



All The Small Things

Glaucoma and Glaucoma Surgery

Joshua Evans, MD

Assistant Professor of Ophthalmology

The Ohio State University Wexner Medical Center



Financial Disclosure

- None

Treating Glaucoma

- The leading cause of irreversible blindness worldwide.
 - 76 million affected
 - 111.8 million predicted for 2040
 - 3 million in the US, direct medical cost of \$2.9 billion
 - Treatment with drops requires significant commitment from patient
 - Laser treatment not always effective

What is Glaucoma?

- Open Angle Glaucoma
 - Most Common
 - Fluid produced in the eye can not drain properly and results in high intraocular pressure (IOP)
 - Elevated pressure directly damages the optic nerve
- Angle Closure Glaucoma
 - Occurs when drain closes abruptly due to iris being very close to drain
 - Rapid increase in pressure
 - Blinding if not treated rapidly

How is it Diagnosed? Treated?

- Less commonly due to eye pain or vision changes
- More commonly detected on routing exams due to minimal/no early symptoms
- Diagnosed formally with visual field testing
- Treatment includes topical drops, laser procedures or surgery

- **GLAUCOMA DOES NOT MEAN ALL PATIENTS WILL GO BLIND**

Old School Glaucoma

- Diagnosis



- Start one drop



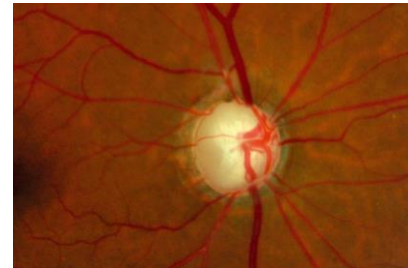
- Start two drops



- Start as many drops as humanly possible

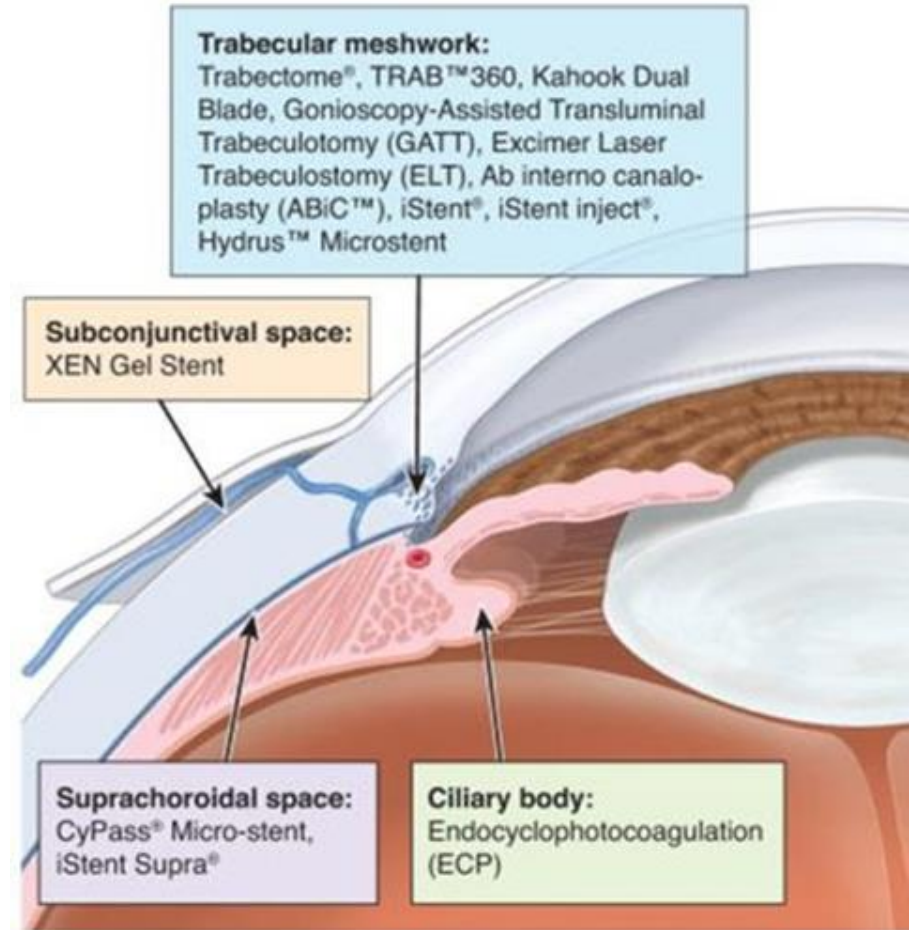


- Trabeculectomy



What is MIGS

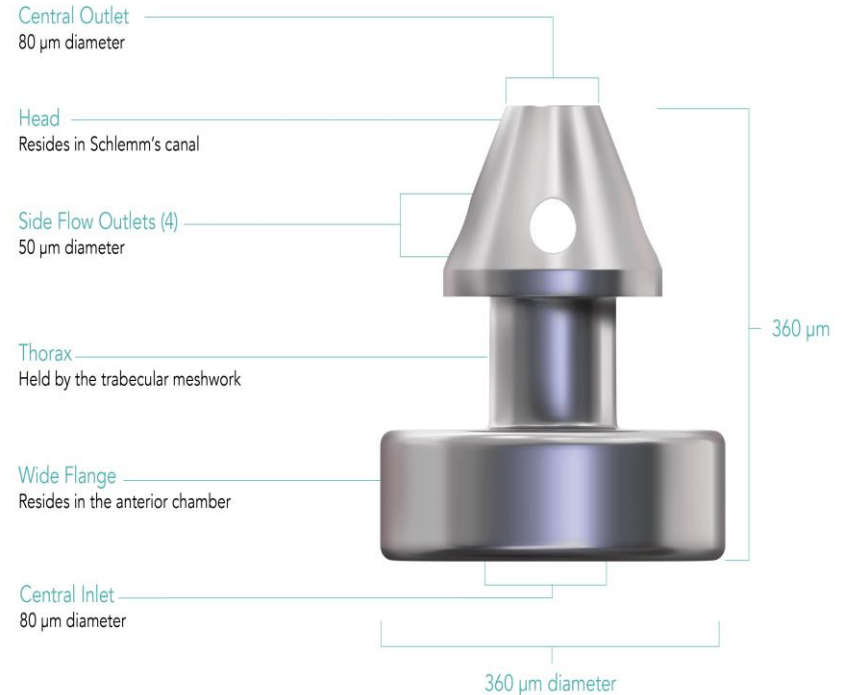
- Coined by Dr. Ike Ahmed in 2009
- Share 5 characteristics
 - High safety profile
 - Protect normal anatomy
 - Ab Interno
 - Efficacy at least 20%
 - Ease of Use



Bypass by Stent

iStent Infinite (G3)

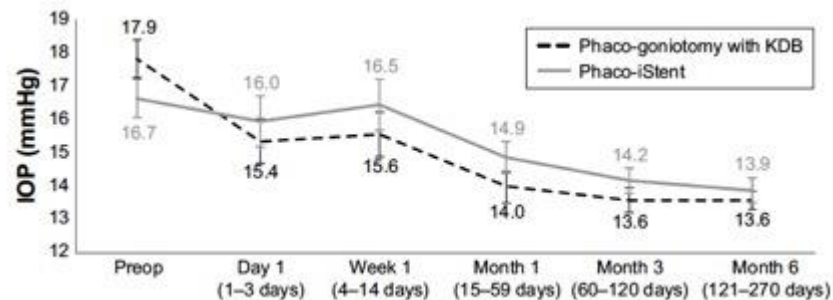
- 360-micron titanium stent
- Can be standalone procedure
- 3 stents in each injector
- 2-3 clock hours apart
- **Does it work?**
 - **Patients with prior failed surgery**
 - **73.4% of patients with >20% reduction in IOP**
 - **47.3% of patients with >30% reduction in IOP**



Bypass by Tissue Excision

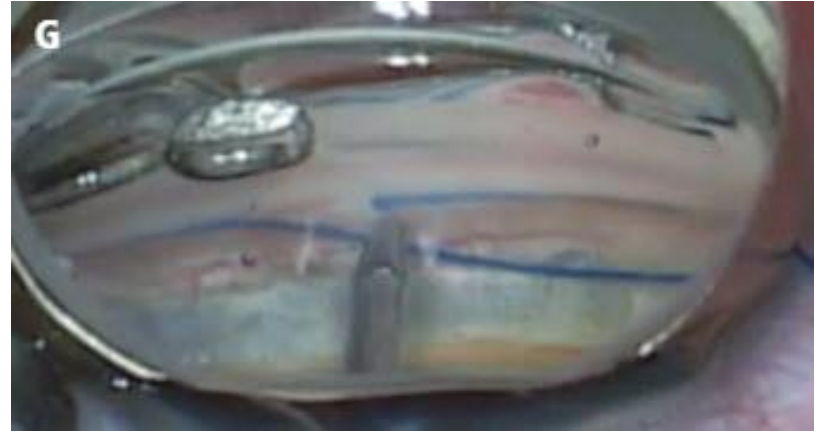
Kahook Dual Blade and GLIDE

- Disposable blade for TM excision
- Two parallel blades incise, and a central ramp removes the TM from the angle
- No implant left in angle, so no long term concerns regarding MRI conditionality or implant migration
- **Does it work?**
 - **Goniotomy with KDB showed greater IOP decrease at all time points vs iStent in multiple RCTs**



GATT (Gonioscopy Assisted Transluminal Trabeculotomy)

- A 360 degree internal unroofing of Schlemm's canal.
- Can be performed with lighted microcatheter or prolene suture
- Very cost effective (with suture)
- No conjunctival manipulation
- Can have significant hyphema



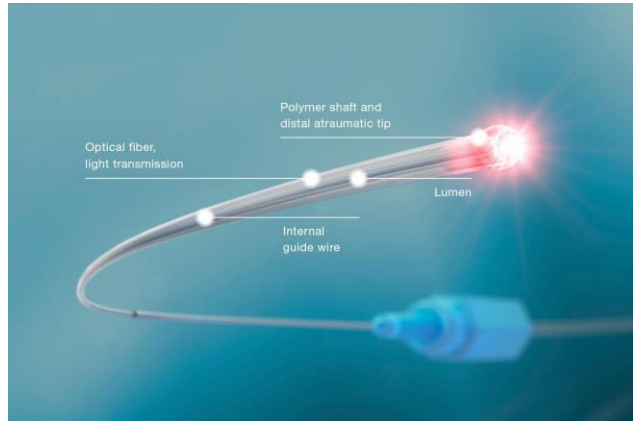
Or... Removing the Stopper



Enhancing Outflow through Schlemm's Canal

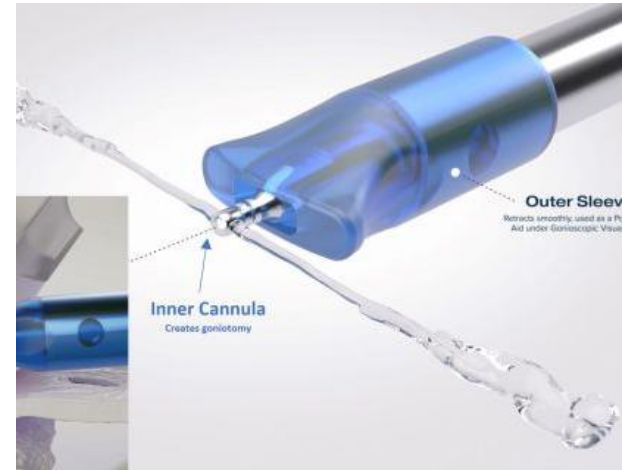ABiC (Ab Interno Canaloplasty) with iTrack

- 250 micron microcatheter with fiber optic light source to allow for visualization of position in Schlemm's canal.
- 360 degree viscodilation performed while withdrawing the catheter

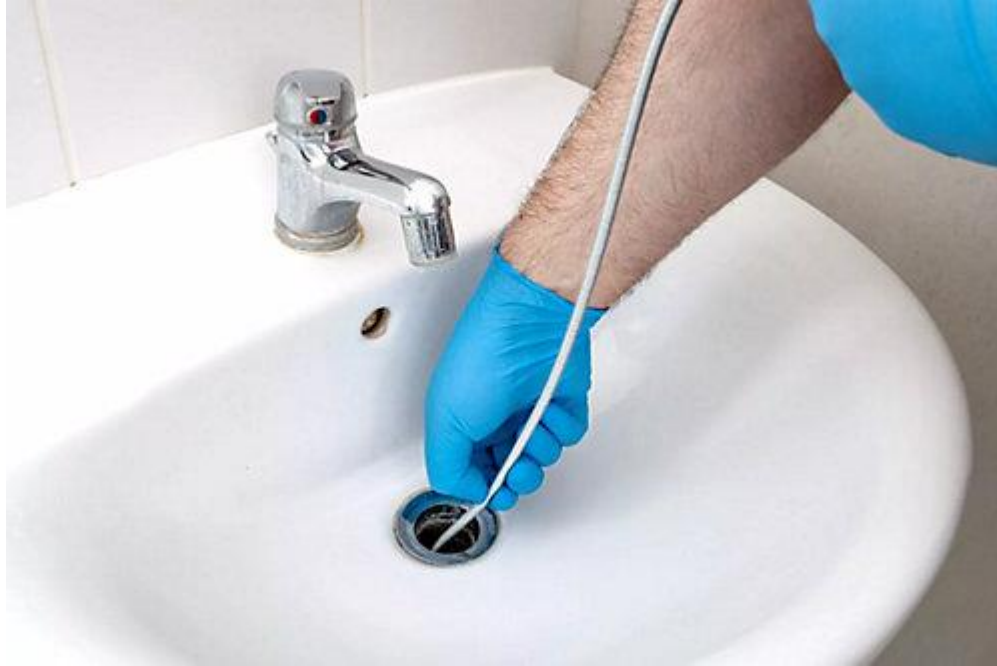

STREAMLINE

- FDA approved 10/8/2021
- Single-use device that creates a 150uM goniotomy and injects viscoelastic
- Device primed for 8 deliveries



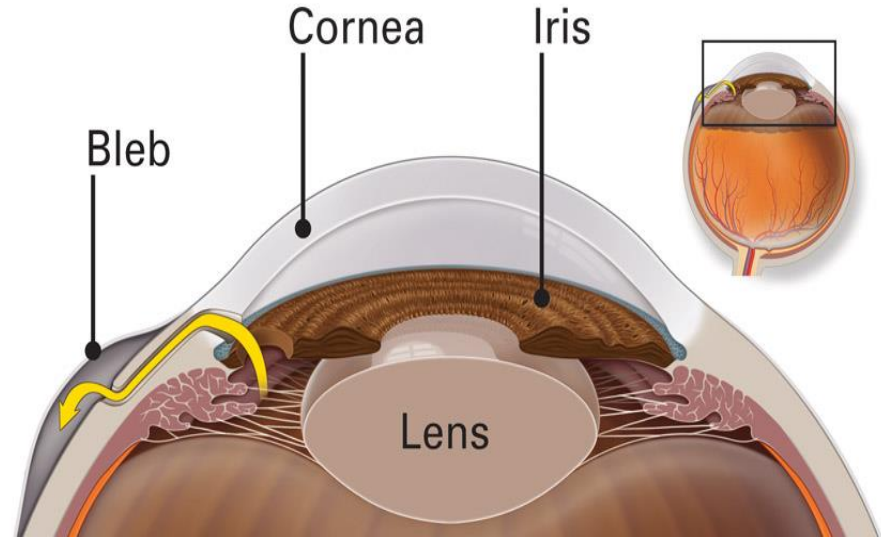
Or... Snaking the Drain



Filtering Surgeries “Old School Glaucoma”

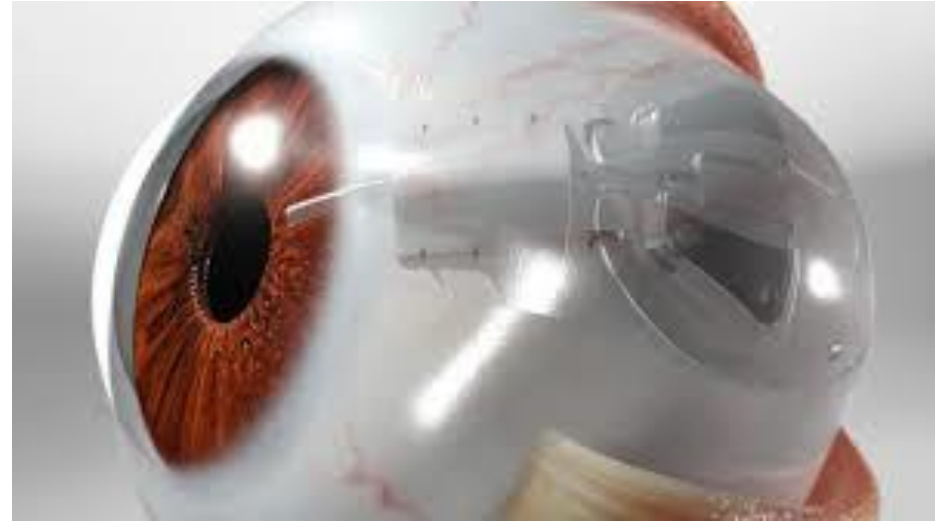
Trabeculectomy

- Partial thickness corneoscleral flap overlying an excised portion of TM and Schlemm's canal that was then sutured.
- Still in heavy use today
- Treated with anti-healing medications to control scarring
- Higher risk, higher reward

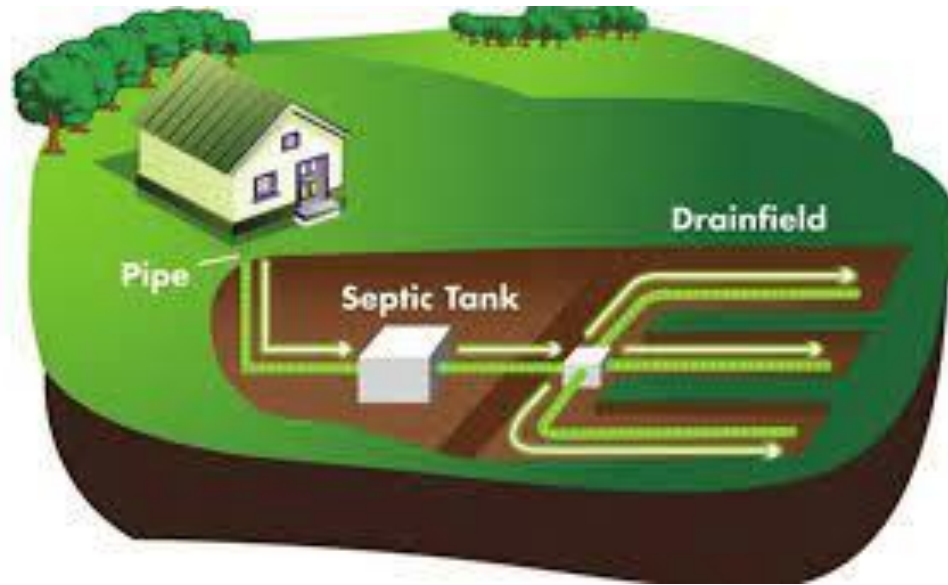

Tube Shunt

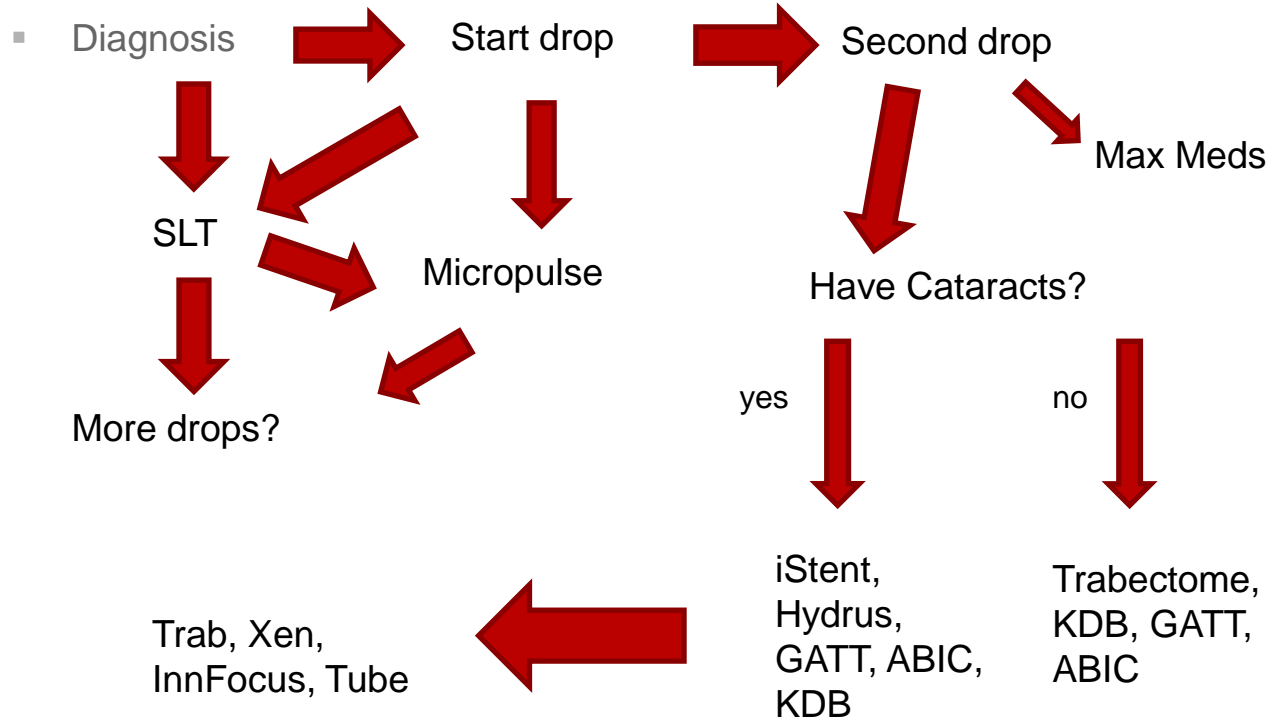
- Small tube sends fluid to reservoir around plate, fluid then reabsorbed by vasculature.
- No need for anti-healing medication
- More predictable, less effective



Or... The Septic System



New Treatment Algorithm



Take Home Message

- There are more treatment methods than ever before:
 - Do they like/can they use drops?
 - How is their compliance?
 - How much vision do they have?
 - Social support?
 - What do they like to do?
 - Where do they live?
- Refer at any time that you feel the patient may gain significant benefit

Thank you!

References

- Anderson, M. G., Libby, R. T., Gould, D. B., Smith, R. S., & John, S. W. M. (2005). High-dose radiation with bone marrow transfer prevents neurodegeneration in an inherited glaucoma. *Proceedings of the National Academy of Sciences of the United States of America*, 102(12), 4566–4571. <http://doi.org/10.1073/pnas.0407357102>
- Brandão, L. M., & Grieshaber, M. C. (2013). Update on Minimally Invasive Glaucoma Surgery (MIGS) and New Implants. *Journal of Ophthalmology*, 2013, 705915. <http://doi.org/10.1155/2013/705915>
- Dorairaj, S. K., Seibold, L. K., Radcliffe, N. M., Aref, A. A., Jimenez-Román, J., Lazcano-Gomez, G. S., ... Berdahl, J. P. (2018). 12-Month Outcomes of Goniotomy Performed Using the Kahook Dual Blade Combined with Cataract Surgery in Eyes with Medically Treated Glaucoma. *Advances in therapy*, 35(9), 1460–1469. doi:10.1007/s12325-018-0755-4
- Gallardo MJ, Supnet RA, Ahmed IIK. [Viscodilatation of Schlemm's canal for the reduction of IOP via an ab-interno approach](#). Clin Ophthalmol. 2018;12:2149-2155. doi: 10.2147/OPHT.S177597. eCollection 2018. PubMed PMID: 30425450; PubMed Central PMCID: PMC6205145.
- Grover DS, Smith O, Fellman RL, Godfrey DG, Gupta A, Montes de Oca I, Feuer WJ. [Gonioscopy-assisted Transluminal Trabeculotomy: An Ab Interno Circumferential Trabeculotomy: 24 Months Follow-up](#). J Glaucoma. 2018 May;27(5):393-401. doi: 10.1097/IJG.0000000000000956. PubMed PMID: 29613978.
- Guedes RAP, Gravina DM, Lake JC, Guedes VMP, Chaoubah A. [One-Year Comparative Evaluation of iStent or iStent inject Implantation Combined with Cataract Surgery in a Single Center](#). Adv Ther. 2019 Aug 22;. doi: 10.1007/s12325-019-01067-5. [Epub ahead of print] PubMed PMID: 31440981.
- Howell, G. R., Soto, I., Zhu, X., Ryan, M., Macalinao, D. G., Sousa, G. L., ... John, S. W. M. (2012). Radiation treatment inhibits monocyte entry into the optic nerve head and prevents neuronal damage in a mouse model of glaucoma. *The Journal of Clinical Investigation*, 122(4), 1246–1261. <http://doi.org/10.1172/JCI61135>
- Malvankar-Mehta, M. S., Iordanous, Y., Chen, Y. N., Wang, W. W., Patel, S. S., Costella, J., & Hutnik, C. M. L. (2015). iStent with Phacoemulsification versus Phacoemulsification Alone for Patients with Glaucoma and Cataract: A Meta-Analysis. *PLoS ONE*, 10(7), e0131770. <http://doi.org/10.1371/journal.pone.0131770>
- Razeghinejad, M.R., & Spaeth G.L. (2011). A History of the Surgical Management of Glaucoma. *Optometry and Visual Sciences*, 2011, Vol 88, No. 1. PP E39-E47.
- Wardani, M.E., Bergin C., Achache F., Sharkawi E. (2015). Evaluating the Trabecular Micro-Bypass Stent Combined with Phacoemulsification compared to Phacoemulsification Alone. *Klin Monatsbl Augenheilkd*. 2015. 232(4): 442-445.
- Wroblewski, D., Francis, B. A., Sadun, A., Vakili, G., & Chopra, V. (2014). Testing of Visual Field with Virtual Reality Goggles in Manual and Visual Grasp Modes. *BioMed Research International*, 2014, 206082. <http://doi.org/10.1155/2014/206082>

References

1. Resnikoff S, Pascolini D, Etyaale D et al. (2004) Global data on visual impairment in the year 2002. *Bull World Health Organ* 82:844–851
2. Tham YC, Li X, Wong TY, Quigley HA, Aung T, Cheng CY. Global prevalence of glaucoma and projections of glaucoma burden through 2040: a systematic review and meta-analysis. *Ophthalmology*. 2014;121:2081–2090
3. Rein DB, Zhang P, Wirth KE, et al. The Economic Burden of Major Adult Visual Disorders in the United States. *Arch Ophthalmol*. 2006;124(12):1754–1760. Doi:10.1001/archopht.124.12.1754
4. Samuelson TW, Chang DF, Marquis R, et al. A Schlemm canal microstent for intraocular pressure reduction in primary open-angle glaucoma and cataract. *Ophthalmology*. 2019;126(1):29-37.